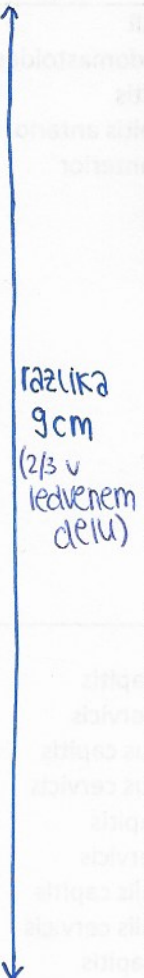
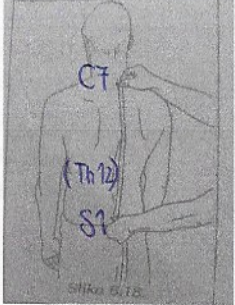

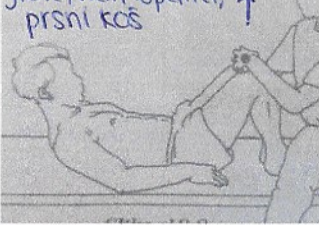
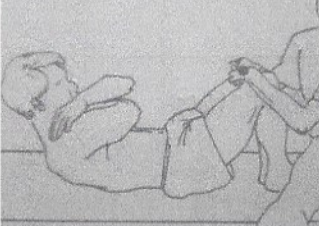
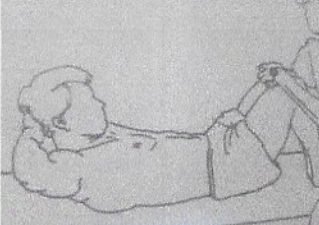
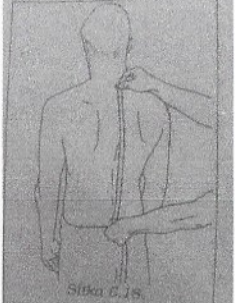


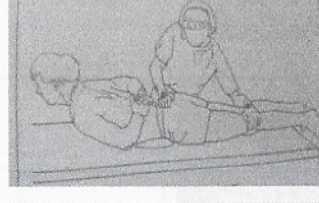


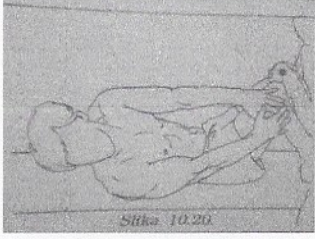
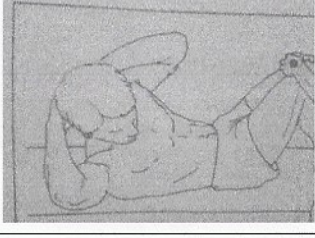
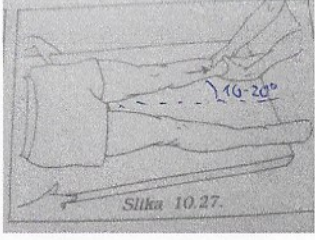


	GIBLIVOST	MTM	
GLAVA in VRAT			
>(ante) fleksija 45°	<p>proruberantia mentale incisura jugularis Slika 6.7</p> <p>proruberantia occipitale C7 Slika 6.8</p> <p>Linearne meritve</p> <p>!zaprta usta</p> <p>← 2 OB GONIOMETROM</p>	<p>Slika 10.2.</p>	<ul style="list-style-type: none"> m. longus colli m. sternocleidomastoideus m. longus capitis m. rectus capitis anterior m. scalenus anterior
>retro fleksija = ekstenzija 45°	<p>!zaprta usta</p>	<p>Slika 10.5.</p>	<ul style="list-style-type: none"> m. trapezius m. splenius capitis m. splenius cervicis m. longissimus capitis m. longissimus cervicis m. spinalis capitis m. spinalis cervicis m. semispinalis capitis m. semispinalis cervicis mm. rectus capitis posterior major et minor
>lateralna fleksija 45°	<p>processus mastoideus acromion Slika 6.11</p> <p>Slika 6.8.</p>		
>rotacija 60°			


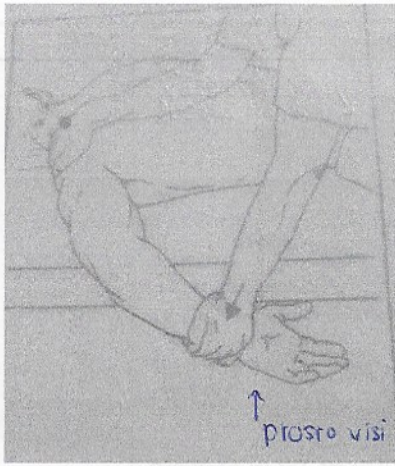
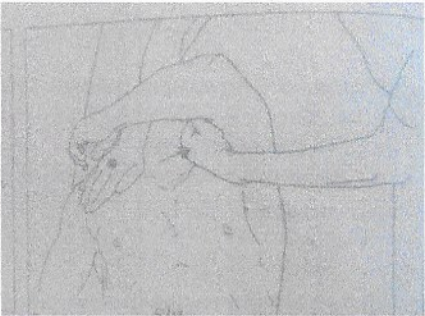
ORIENTACIJSKO: razen pri rotaciji ne dokončujem giba!

	GIBLJIVOST	MTM	
<p>TRUP</p> <p>>fleksija</p>  <p>razlika 9cm (2/3 v ledvenem delu)</p>		<p>glava, vrat, lopatice ↑</p>  <p>ocena 2: 5x</p> <p>pojema joč gib</p> <p>glava, vrat, lopatice, prsni koš ↑</p>  <p>ocena 3: 5x</p>  <p>ocena 4: 1x</p>  <p>ocena 5: 1x</p>	<p>m. rectus abdominis</p>
<p>>ekstenzija</p>		<p>glava, vrat, ramena, 1/2 prsnice ↑</p>  <p>ocena 2: 5x</p> <p>pojema joč</p> <p>glava, vrat, ramena, 1/2 prsnice ↑</p>  <p>ocena 3: 5x</p>  <p>ocena 4: 1x</p>  <p>ocena 5: 1x</p>	<p>m. multifidus m. longissimus thoracis m. spinalis thoracis m. semispinalis thoracis m. iliocostalis thoracis m. iliocostalis lumborum</p>

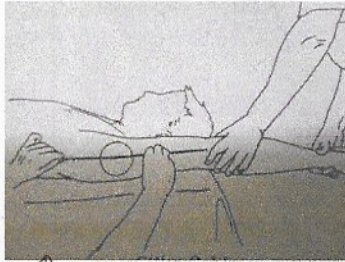

	GIBLJIVOST	MTM	
>rotacija		<p>Obrat po podlagi (obe lopatici od podlage)</p>  <p>Slika 10.19</p> <p>ocena 3: 5x</p>  <p>Slika 10.20</p> <p>ocena 4: 1x</p>  <p>ocena 5: 1x</p>	<p>m. obliquus externus abdominis m. obliquus internus abdominis</p> <p>najprej rot. potem flex.</p>
>elevacija medenice		 <p>Slika 10.27</p>	<p>m. quadratus lumborum</p>



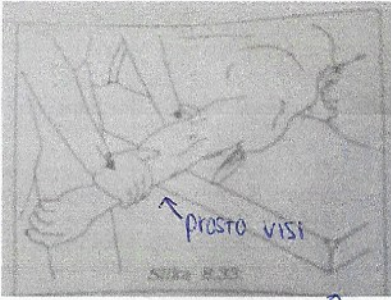
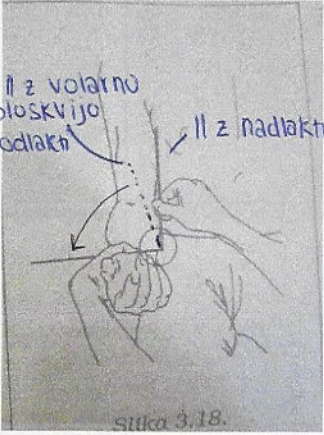
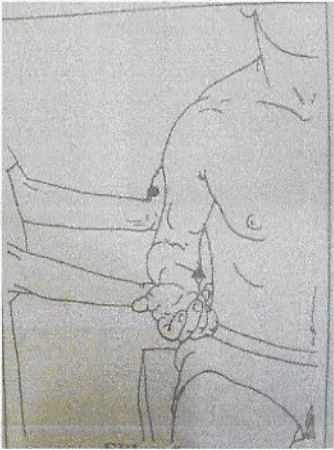
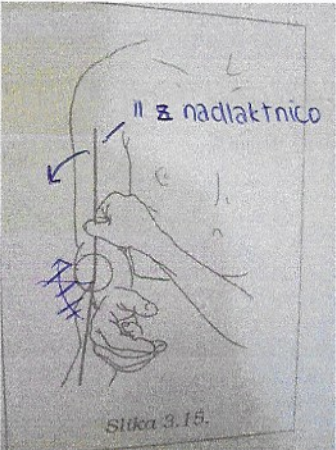
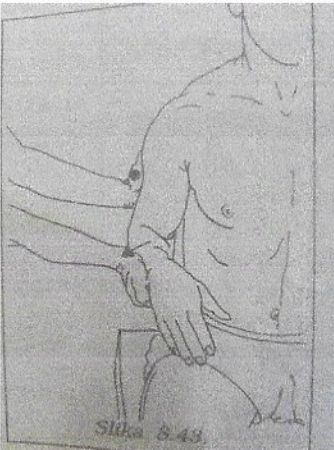
OPISNO

RAMENSKI SKLEP	GIBLJIVOST	MTM	90°
<p>>antefleksija</p> <p>90°</p>	<p>!! nasprotni zg. ud je za glavo</p>	<p>Slika 8.2</p>	<p>m. deltoideus m. coracobrachialis</p>
<p>>retroflexija</p> <p>50°</p>	<p>Slika 8.3</p>	<p>Slika 8.4</p>	<p>m. latissimus dorsi m. teres major m. deltoideus</p>
<p>>abdukcija</p> <p>90°</p>	<p>Slika 8.5</p> <p>!! nasprotni zg. ud = za glavo!</p>	<p>Slika 8.6</p>	<p>m. supraspinatus m. deltoideus</p>
<p>>zunanja rotacija</p> <p>90°</p>	<p>Slika 8.7</p> <p>!! nasprotni zg. ud = za glavo!!</p>		<p>m. infraspinatus m. teres minor</p>

<p>>notranja rotacija</p> <p>70°</p>	 <p>Slika 3.7.</p>	 <p>↑ prosro visi</p>	<p>m. subscapularis m. teres major</p>
<p>>horizontalna addukcija</p>	<p>/</p>		<p>m. pectorails major</p>

!! nasprotni zg.ud = za glavo!

	GIBLIVOST	MTM	
<p>RAMENSKI OBROČ</p>			
<p>>elevacija skozi antefleksijo</p> <p>180°</p>	 <p>!! nasprotni zg.ud = za glavo!</p>	<p>/</p>	
<p>>elevacija skozi abdukcijo</p> <p>170°</p>	 <p>Slika 3.10.</p>	<p>/</p>	

	GIBLJIVOST	MTM	
KOMOLČNI SKLEP IN PODLAKET			
>fleksija 145°			m. biceps brachii (supinacija) m. brachioradialis (ničelen položaj) m. brachialis (pronacija).
>ekstenzija	Hiperekstenzija (meritev kot pri fleksiji)		m. triceps brachii m. anconeus
>supinacija 90°			m. supinator m. biceps brachii
>pronacija 85°			m. pronator teres m. pronator quadratus
!!!	Valgus in varus položaj v komolčnem sklepu		

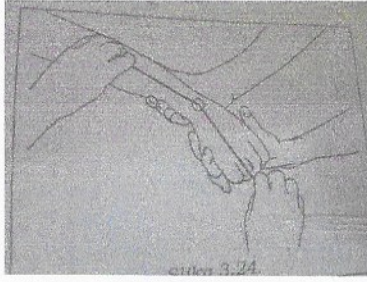lahko tudi reže na Hrbtu ←

	GIBLIVOST	MTM	
ZAPESTNI SKLEP >dorzalna fleksija 70°			m. extensor carpi ulnaris m. extensor carpi radialis
>volarna fleksija 80°			m. flexor carpi ulnaris m. flexor carpi radialis
>ulnarna abdukcija 30°		m. extensor carpi ulnaris m. extensor carpi ulnaris	

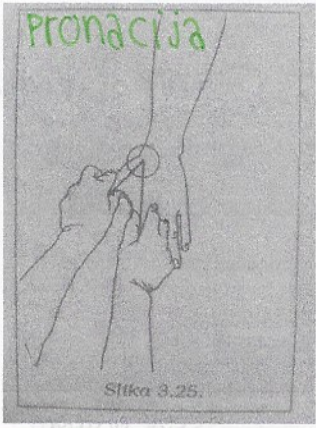
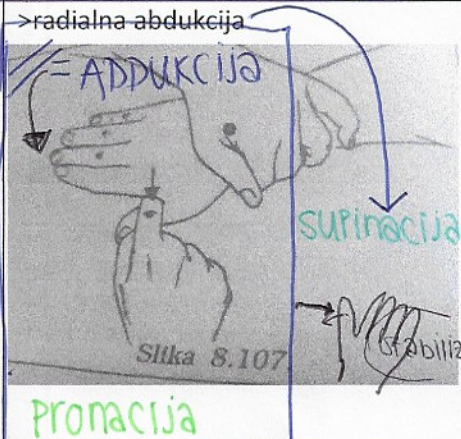
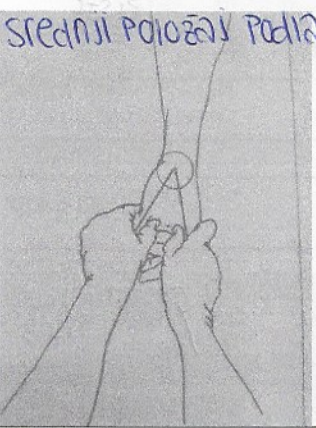


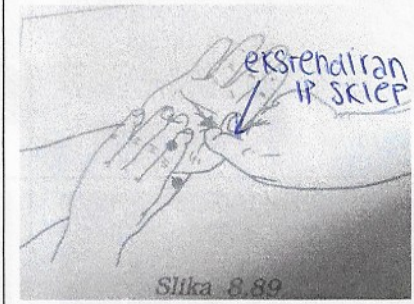
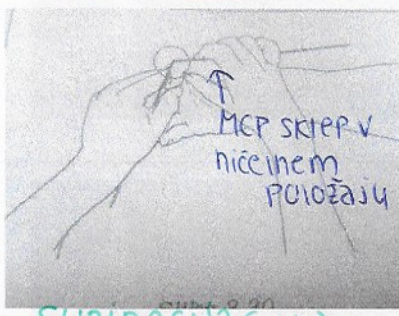
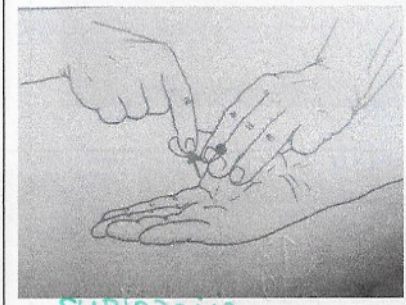

meriš na lateralni strani zapestja



>radialna
abdukcija




20°

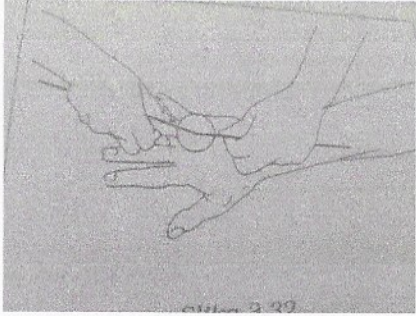



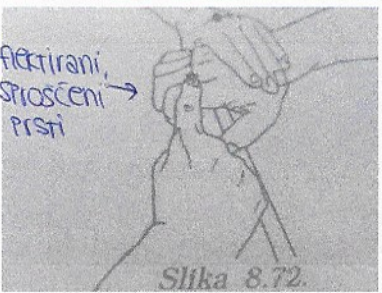





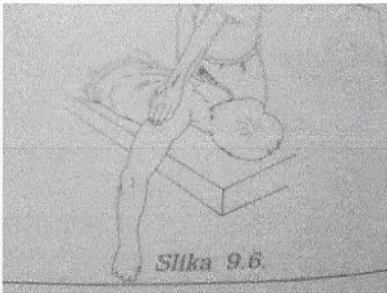

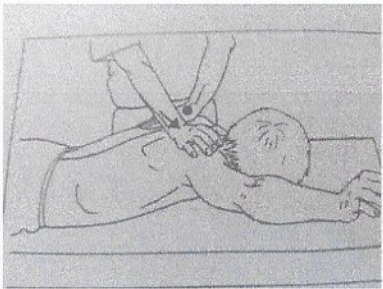

m. extensor carpi radialis
m. flexor carpi radialis

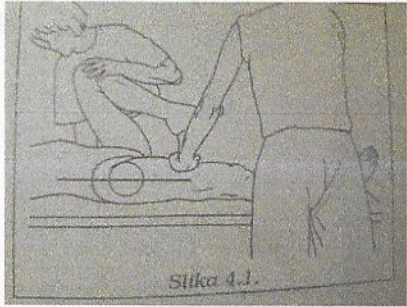

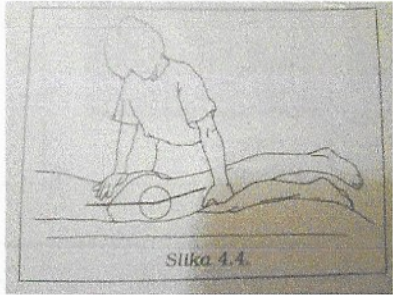
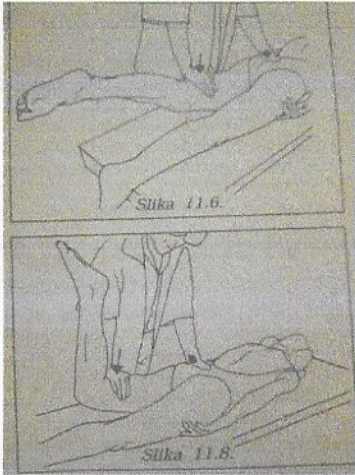
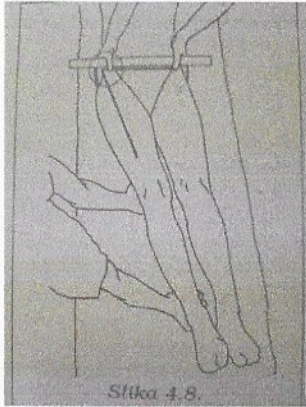
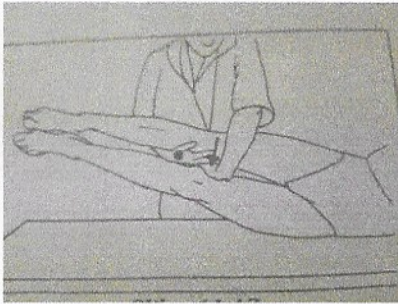
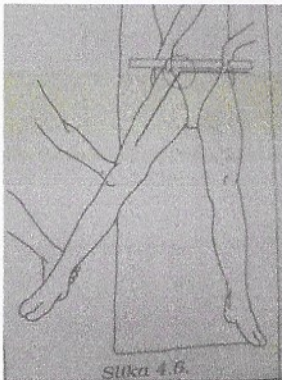
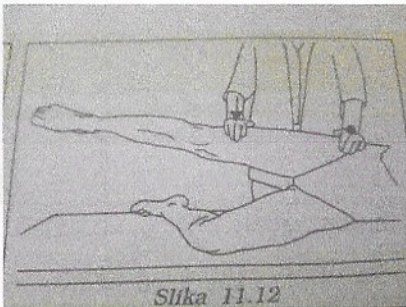
	GIBLIVOST	MTM	
PALEC NA ROKI >ekstenzija v CMC sklepu 60°	 <p>Pronacija Slika 8.25.</p>	 <p>>radialna abdukcija = ADDUKCIJA Supinacija Slika 8.107 (stabilizacija) Pronacija</p>	m. abductor pollicis longus
>abdukcija v CMC sklepu 60°	<p>Srednji položaj podlakti</p> 	>palmarna abdukcija  <p>Slika 8.101. Supinacija</p>	m. abductor pollicis brevis
>fleksija v MCP sklepu 55°	<p>ekstendiran IP sklep</p>  <p>Supinacija</p>	 <p>ekstendiran IP sklep Slika 8.89 Supinacija</p>	m. flexor pollicis brevis
>fleksija v IP sklepu 85°	<p>MCP sklep v ničelnem položaju</p>  <p>Supinacija (gaha)</p>	 <p>Supinacija</p>	m. flexor pollicis longus
>ekstenzija v MCP sklepu		<p>Srednji položaj podlakti → MCP in IP sklep v fleksiji</p>  <p>Slika 8.95.</p>	m. extensor pollicis brevis

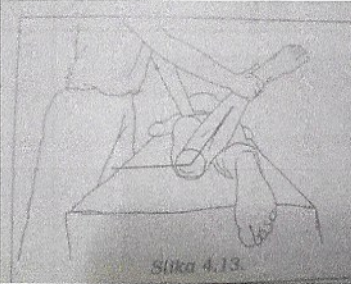


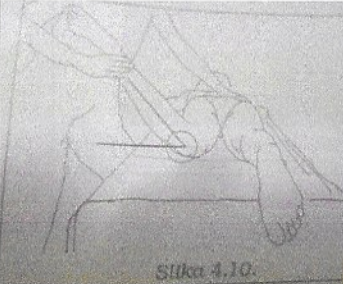


<p>>ekstenzija v IP sklepu</p>		<p>SREDNJI POLOŽAJ PODLAKTI</p>	<p>m. extensor pollicis longus</p>
<p>>opozicija palca in mezinca</p>		<p>SUPINACIJA</p>	<p>m. opponens pollicis m. opponens digiti minimi</p>

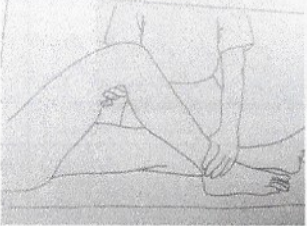
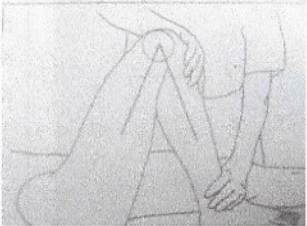
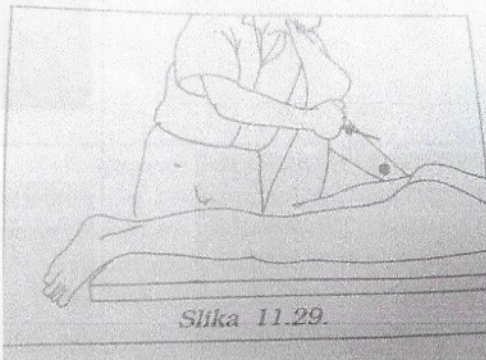
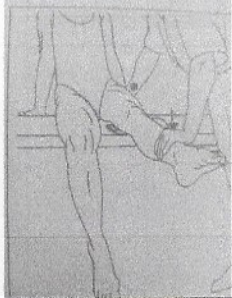

	GIBLJIVOST	MTM	
<p>OSTALI PRSTI ROK</p>			
<p>>fleksija v MCP sklepah</p> <p>30° (narasča I → IV. prst)</p>	<p>nicejni položaj</p> 	<p>SUPINACIJA</p>	<p>m. lumbricales manus</p>
<p>>fleksija v PIP sklepah</p> <p>100°</p>	<p>nicejni položaj</p>  <p>Slika 3.34.</p>	<p>SUPINACIJA</p>	<p>m. flexor digitorum superficialis</p>
<p>>fleksija v DIP sklepah</p> <p>80°</p>	<p>nicejni položaj</p>  <p>70° fleksije v PIP sklepu</p>	<p>SUPINACIJA</p>	<p>m. flexor digitorum profundus</p>

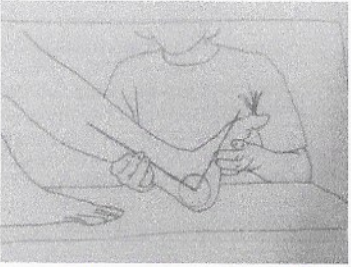

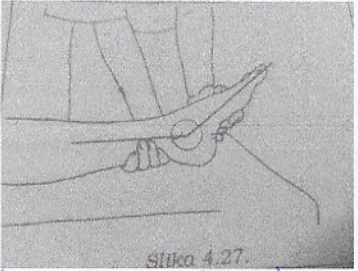
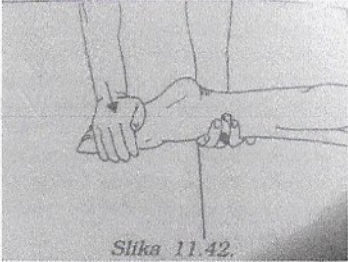
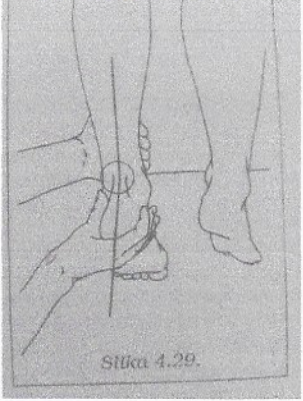
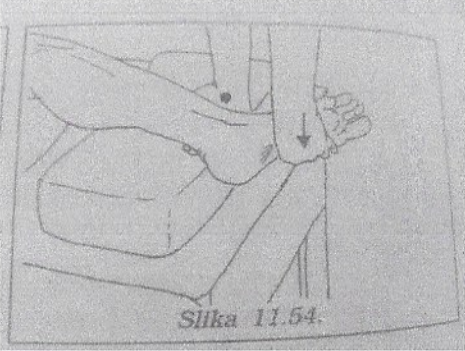
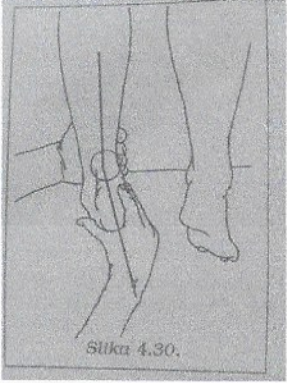
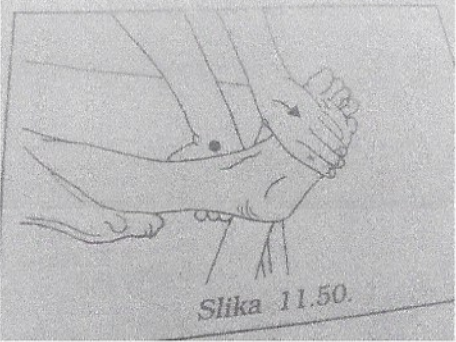
<p>>abdukcija v MCP sklepah</p> <p>45°</p>	 <p>PRONACIJA</p>	<p>PRONACIJA</p>   <p>SUPINACIJA</p>	<p>mm. interossei dorsales manus</p> <p>m. abductor digiti minimi</p>
<p>>ekstenzija v MCP sklepah</p>		<p>flektirani, sproščeni prsti</p>  <p>Slika 8.72.</p> <p>PRONACIJA</p>	<p>m. extensor digitorum communis</p> <p>m. extensor indicis</p> <p>m. extensor digiti minimi</p>
<p>>addukcija v MCP sklepah</p>		<p>stegnjeni prsti</p>  <p>Slika 8.82.</p> <p>PRONACIJA</p>	<p>m. interossei volares manus</p>





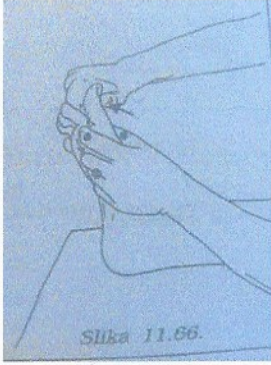
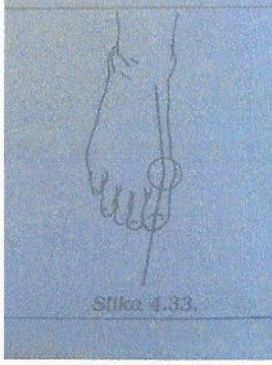
	GIBLJIVOST	MTM	
RAMENSKI OBROČ - LOPATICE			
>elevacija		 Slika 9.2.	m. levator scapula m. trapezius
>addukcija	>addukcija medialnega roba merimo razdaljo med hrbtenico in sredino medialnega roba lopatice (L) pred in po tetrafciji ramen.	 Slika 9.6.	m. trapezius
>addukcija in notranja rotacija	>primik spodnjega vogala merimo razdaljo med spodnjim vogalom lopatice in Th7	 Slika 9.11.	m. rhomboideus major m. rhomboideus minor
>addukcija in depresija		 Slika 9.12.	m. trapezius
>abdukcija in zunanja rotacija	>odmik spodnjega vogala in abdukcija medialnega roba >razdalja med spodnjim vogalom lopatice in Th7 > razdalja med hrbtenico in sredino medialnega roba lopatice (L)	 Slika 9.18.	m. serratus anterior

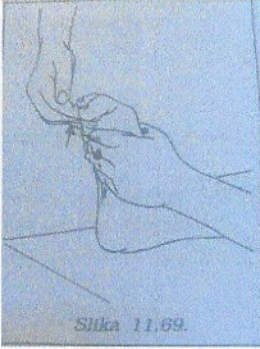

	GIBLJIVOST	MTM	
KOLČNI SKLEP >(ante)flexija	 <p>Slika 4.1.</p>	 <p>Slika 11.2.</p>	m. psoas major m. iliacus
>retroflexija = ekstenzija	 <p>Slika 4.4.</p>	 <p>Slika 11.6.</p> <p>Slika 11.8.</p>	m. gluteus maximus
>addukcija	 <p>Slika 4.8.</p>		m. adductor brevis m. adductor longus m. adductor magnus m. pectineus m. graciles
>abdukcija	 <p>Slika 4.6.</p>	 <p>Slika 11.12.</p>	m. gluteus medius

	GIBLIVOST	MTM	
>zunanja rotacija	 		m. piriformis m. obturatorius externus et internus m. gemellus superior et inferior m. quadratus femoris
>notranja rotacija	 		m. gluteus minimus

	GIBLIVOST	MTM	
KOLENSKI SKLEP			
>fleksija	 		m. biceps femoris m. semimembranosus m. semitendinosus
>ekstenzija			m. rectus femoris m. vastus medialis m. vastus lateralis m. vastus intermedius
!!!	Q-kot, valgus, varus 		

	GIBLJIVOST	MTM	
ZGORNJI SKOČNI SKLEP			
>dorzalna fleksija	 <p>!na lateralni strani!</p>	 <p>↑ skrčeni prsti</p> <p>Slika 11.38.</p>	m. tibialis anterior
>plantarna fleksija	 <p>Slika 4.27.</p> <p>!na lateralni strani!</p>	 <p>Slika 11.42.</p>	m. soleus m. gastrocnemius m. plantaris
>everzija	 <p>Slika 4.29.</p>	 <p>Slika 11.54.</p>	
>inverzija	 <p>Slika 4.30.</p>	 <p>Slika 11.50.</p>	

	GIBLJIVOST	MTM	
PALEC NA NOGI >fleksija v MCP sklepu	 <p>Slika 4.32.</p>	 <p>Slika 11.60.</p>	m. flexor hallucis brevis
>fleksija v IP sklepu		 <p>Slika 11.63.</p>	m. flexor hallucis longus
>ekstenzija v IP sklepu		 <p>Slika 11.66.</p>	m. extensor hallucis longus
HALLUX VALGUS	 <p>Slika 4.33.</p>		

	GIBLIVOST	MTM	
OSTALI PRSTI			
>fleksija prstov		 <p>Slika 11.69.</p>	<p>m. flexor digitorum longus m. flexor digitorum brevis m. lumbricales pedis</p>
>ekstenzija prstov		 <p>Slika 11.71.</p>	<p>m. extensor digitorum longus m. extensor digitorum brevis</p>