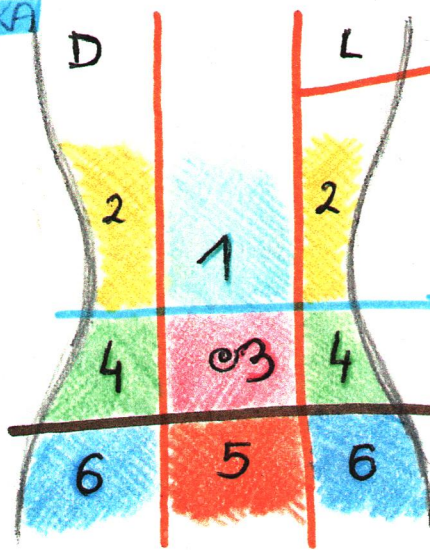


**TOMOGRAFSKA
DELITEV
TREBUSNE
STENE**



MEDIOKLAVIKULARNA RAVNINA

- 1 - EPIGASTRIČNA REGIJA
- 2 - DESNI IN LEVI HIPOHONDRIJ
- 3 - UMBILIKALNA / POPKOVA REGIJA

SUBKOSTALNA RAVNINA

- 4 - DESNA IN LEVA LATERALNA REGIJA

TRANSTUBERKULARNA RAVNINA

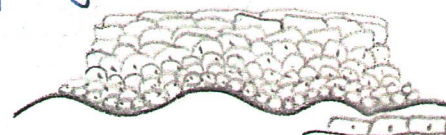
- 5 - PUBIČNA REGIJA
- 6 - DESNA IN LEVA INGVINALNA REGIJA

**EPITELIJSKO
TIPO:**

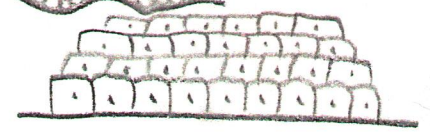
* **pravilni visokopriamatski epitelij**



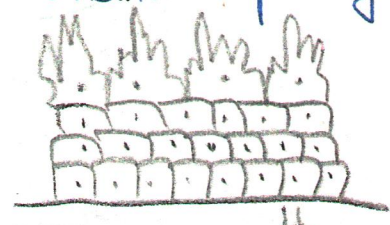
* **nepravilni ploščati epitelij**



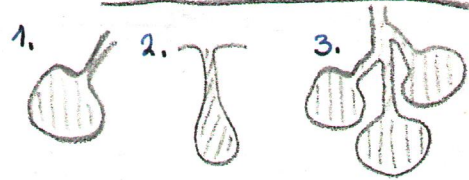
* **nepravilni visokopriamatski epitelij**



* **nepravilni visokopriamatski epitelij**



* **žlezni epitelij**



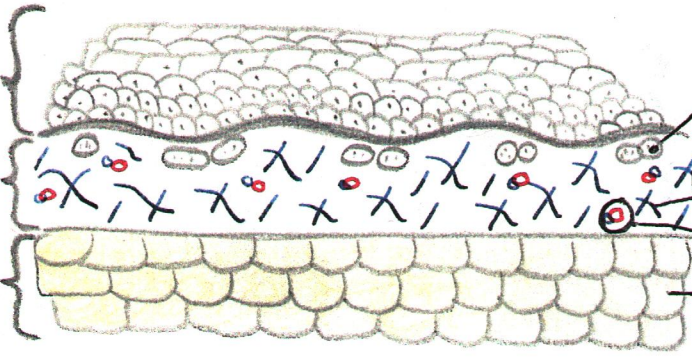
1. MEŠIČKASTA - ALVEOLARNA ŽLEZA
2. CEVASTA - TUBULARNA ŽLEZA
3. KOMBINIRANA; CEVASTO-TUBULARNA ŽLEZA

VEŽIVA: KOŽA

EPIDERMIS
nežlezni epitelij

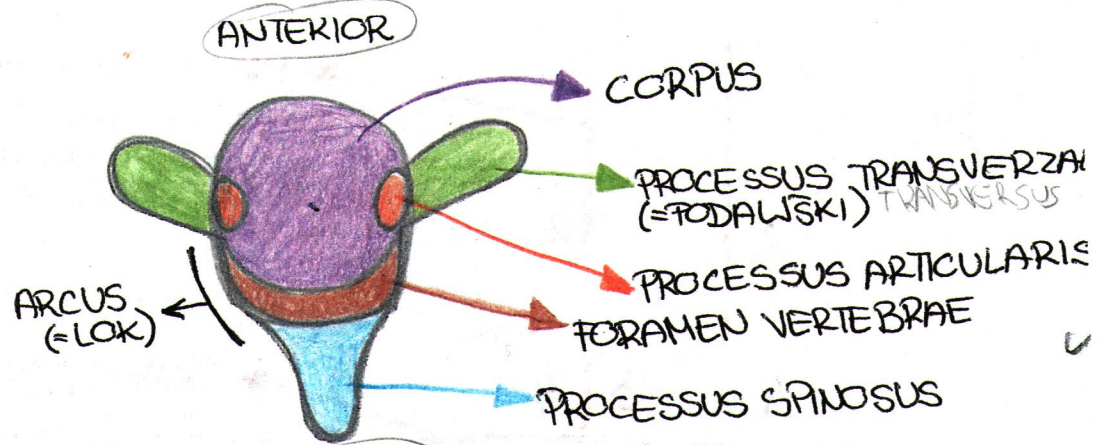
DERMIS

HIPODERMIS

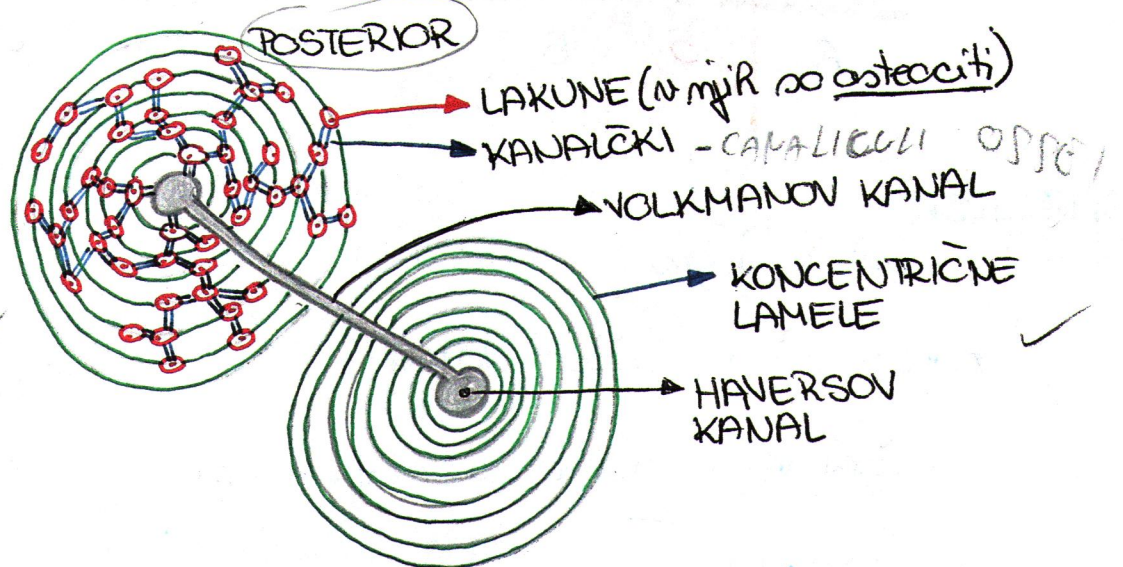


- ŽIVČNI KONČIČI
- BAZALNA MEMBRANA
- ELASTIČNA VLAKNA
- KOLAGENSKA VLAKNA
- ARTERIOLE IN VENULE
- MAŠČOBNE CELICE

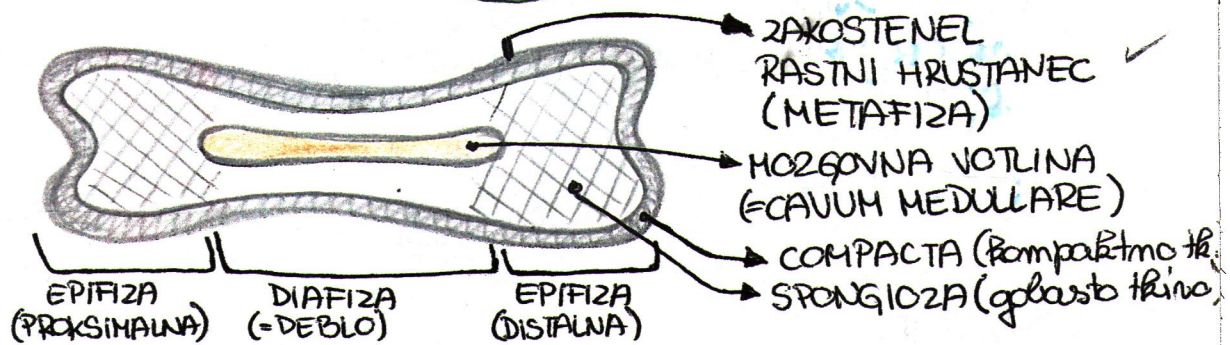
SKUS TERVEKTEBRALIS
POGLED OD ZGORAJ



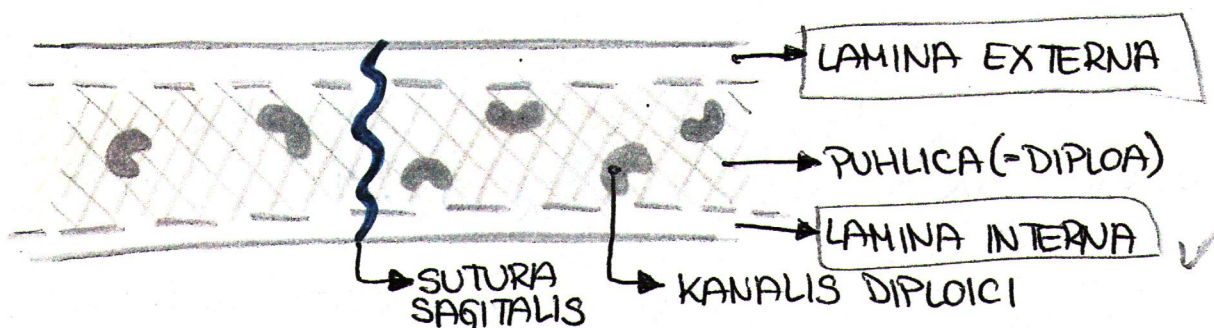
KOSTNINA: PRECNI PREREZ
KOSTINE (OSTEON)



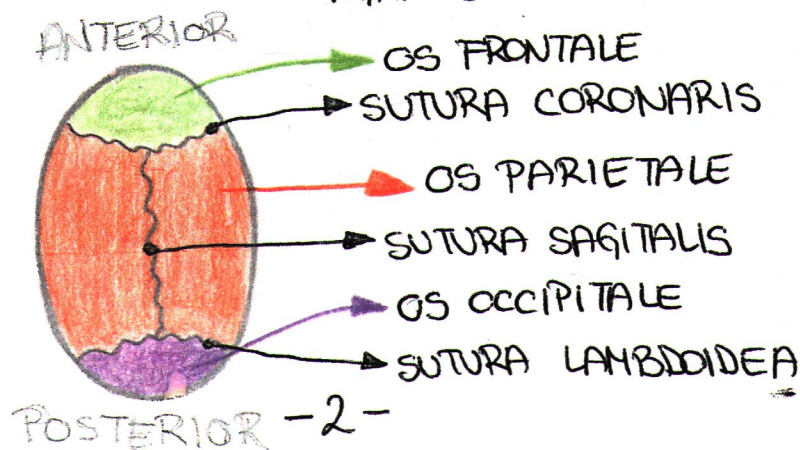
FRONTALNI PREREZ
DOLGE KOSTI



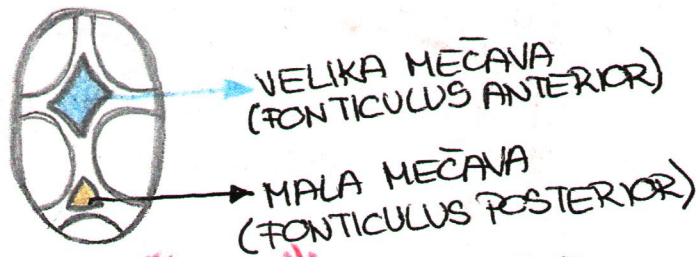
FRONTALNI PREREZ
PLOSKATE KOSTI



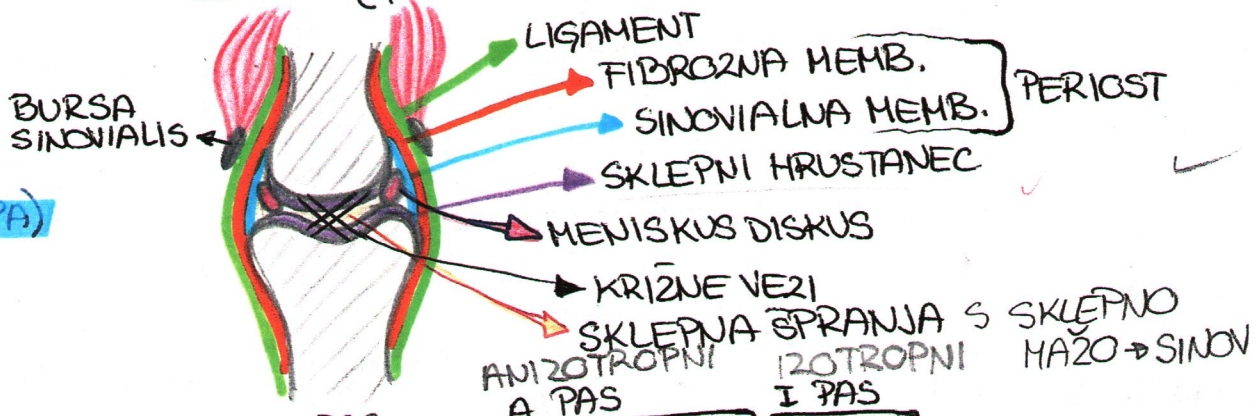
KOSTI GLAVE: LOBFINJA
OD ZGORAJ
ODRASLEGA CLOVEKA



**MEČAVE
= FONTANELE
OVOKOJENČKA**

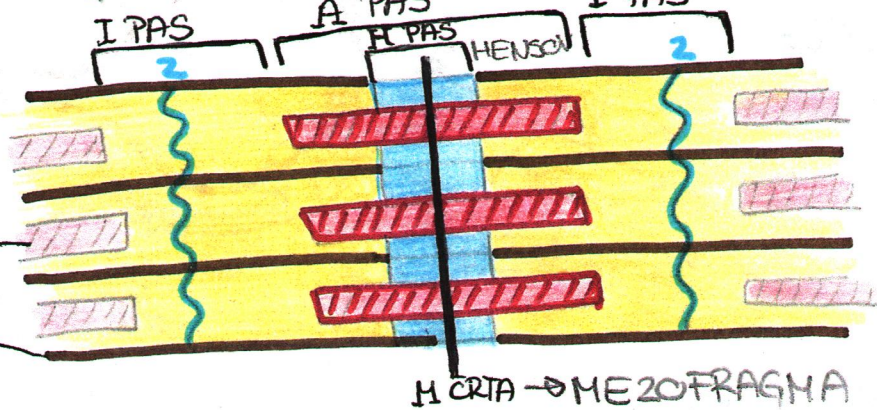


**FRONTALNI
PRERES
DIARTROZE
PRAVEGA SKLEPA)**

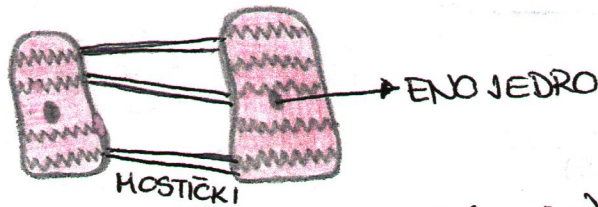


MISICE: SARKOMERA


MIOZINSKI MIOFILAMENTI
AKTINSKI MIOFILAMENTI



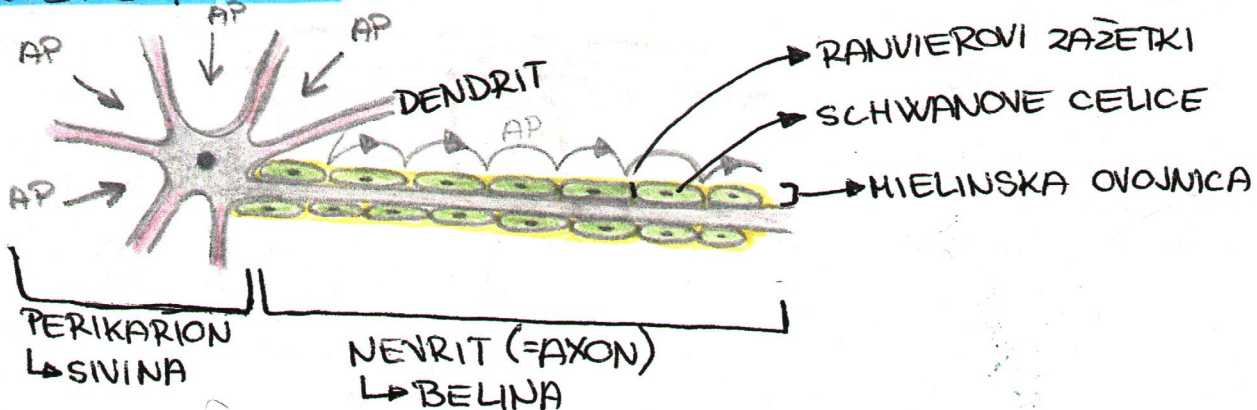
BRONA MUSKULATURA



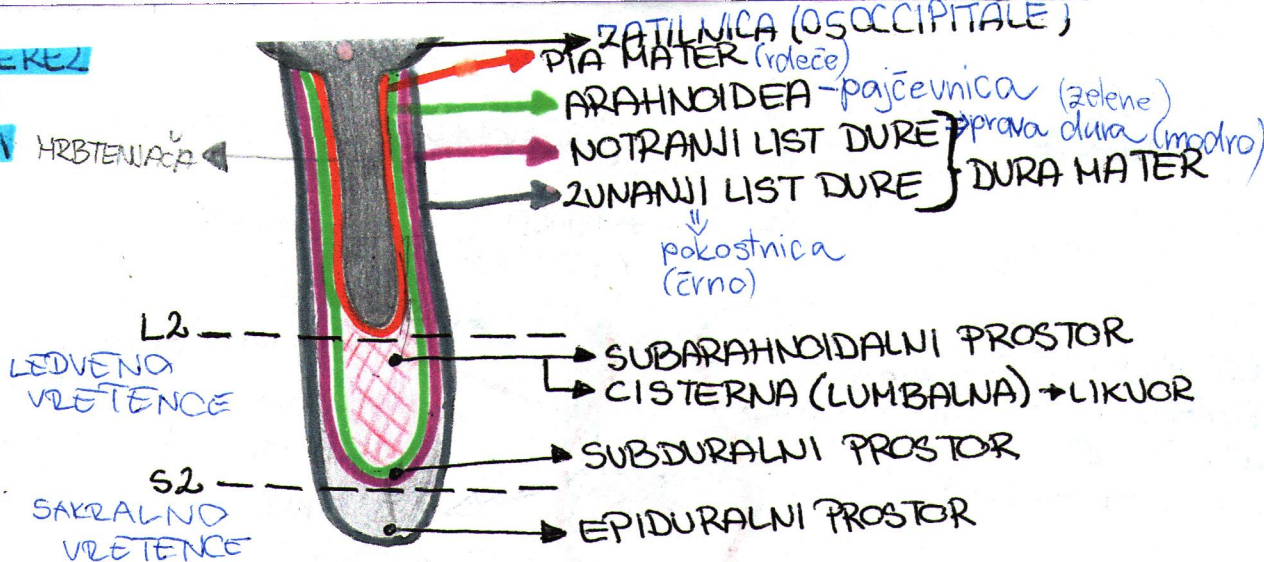
**SKLETNE
MISICE**



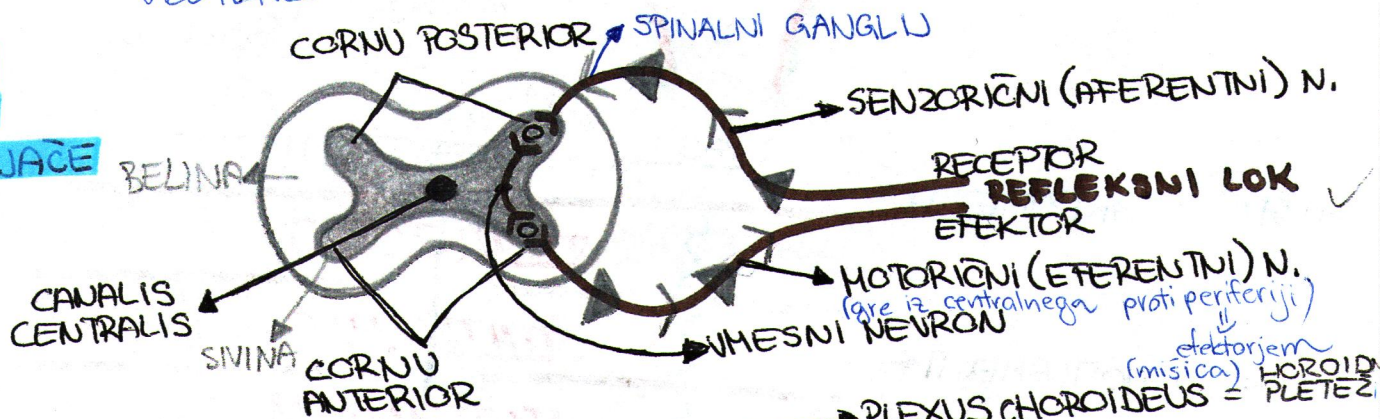
ZVENCEVJE: NEVRON



**FRONTALNI PREREZ
HRBTENJACE
S OVOJNICAMI**

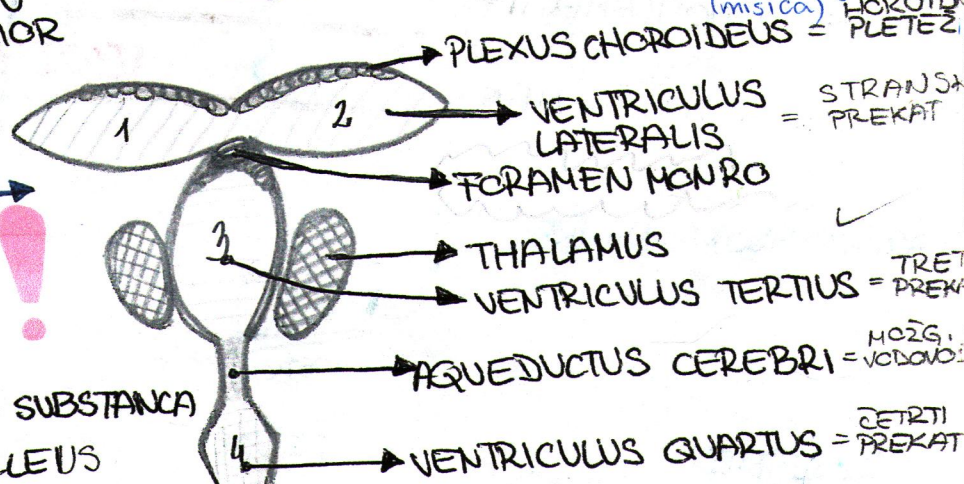


**PREČNI
PREREZ
HRBTENJACE**

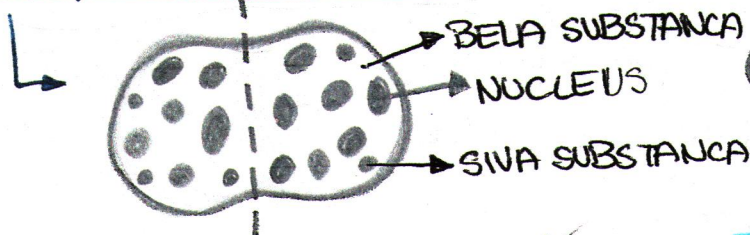


**VELIKI MOZGANI:
MOZGANSKI PREKATI**

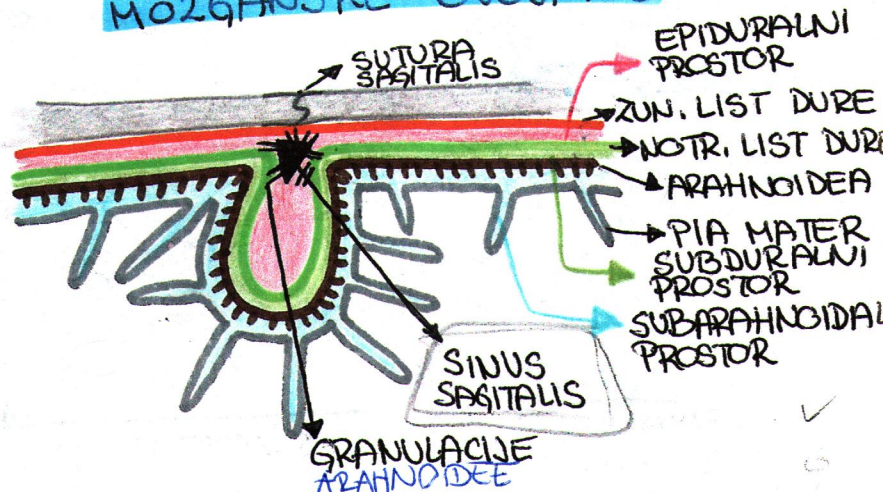
VENTRIKULUS



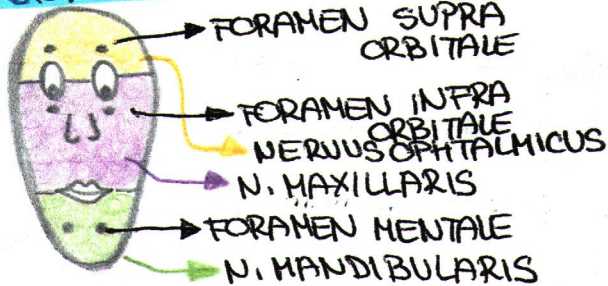
**PREČNI PREREZ
MOZGANSKEGA DEBLA**



**FRONTALNI PREREZ
MOZGANSKE OVOJNICE**

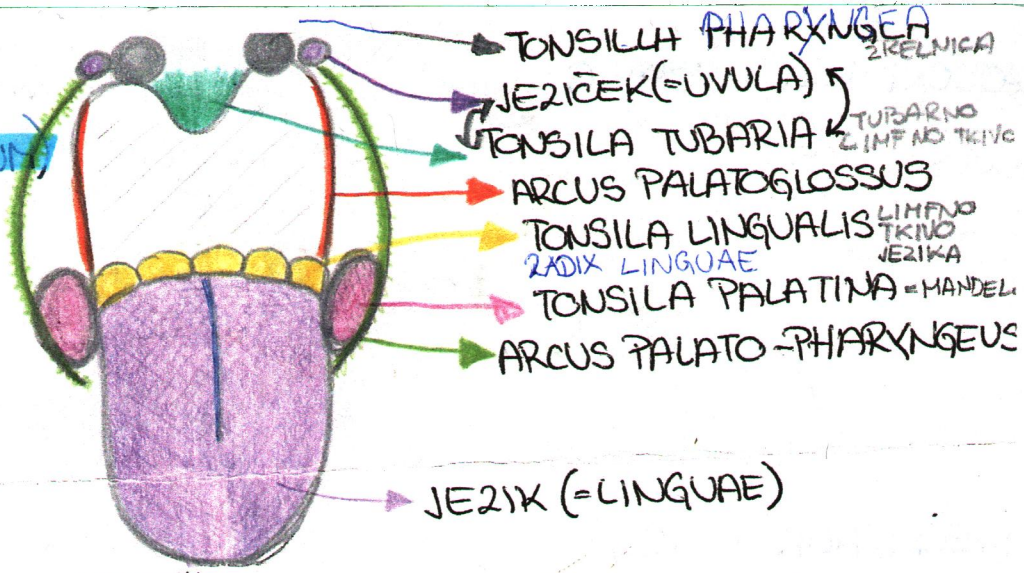


OBRAZNI ZINCI

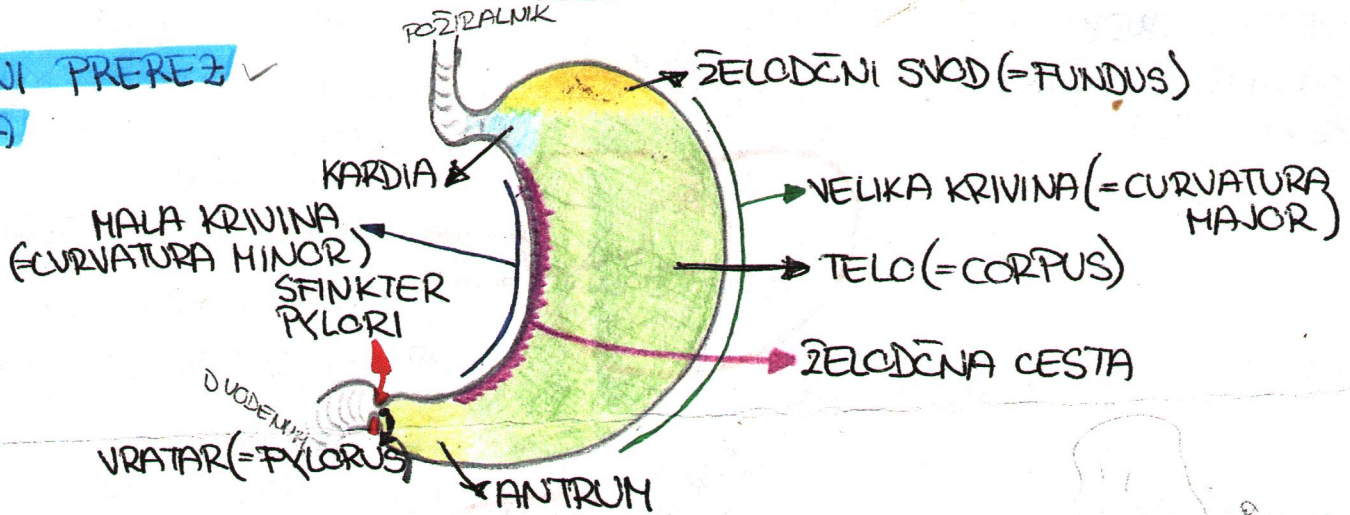


**PREBANILA: GOLTNA
CZINA
(ISTHMUS FANCIUM)**

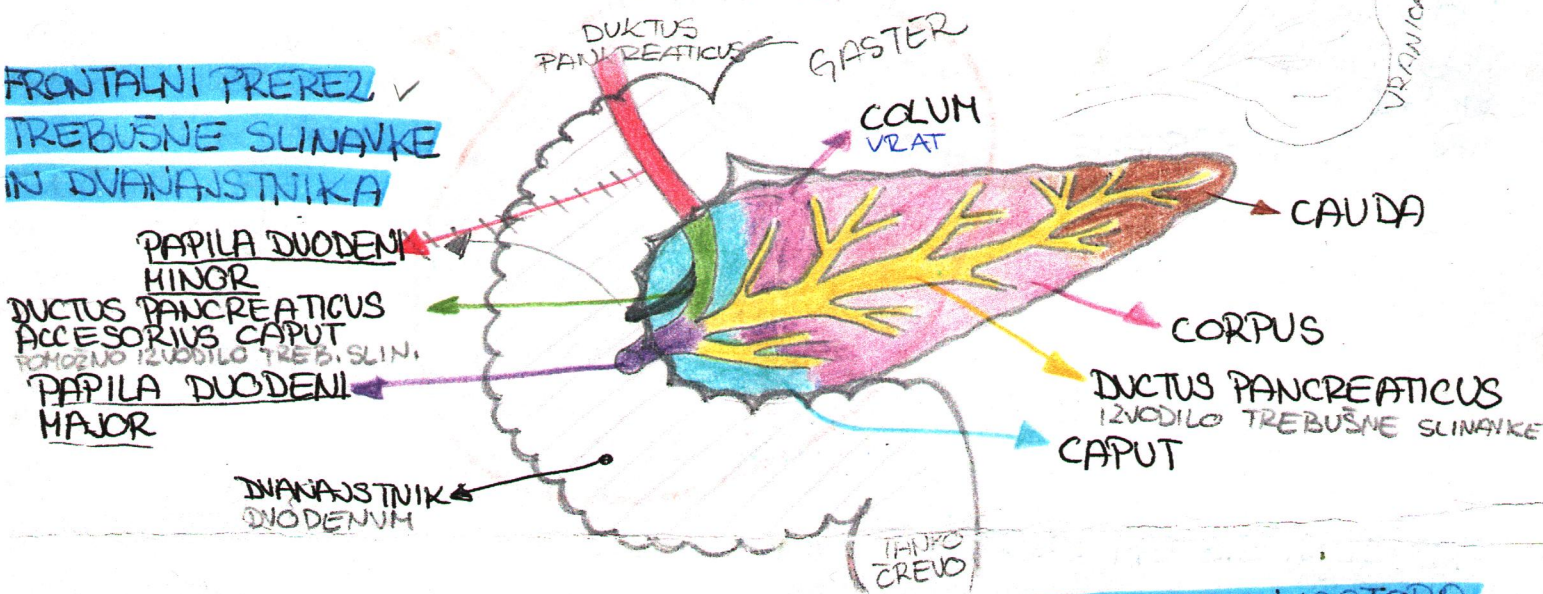
WALDEYER-JEV
OBLOČ



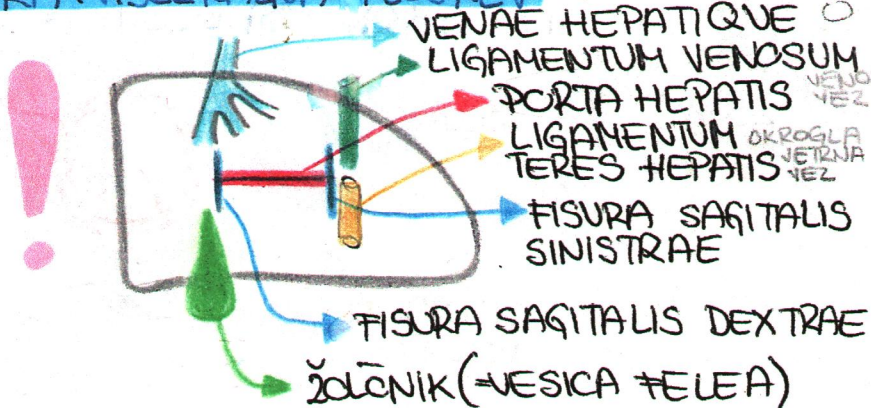
**FRONTALNI PREREZ
ŽELODCA**



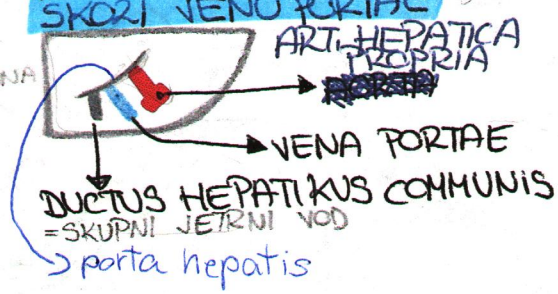
**FRONTALNI PREREZ
TREBUŠNE SLINAVKE
IN DVANAJSTNIKA**

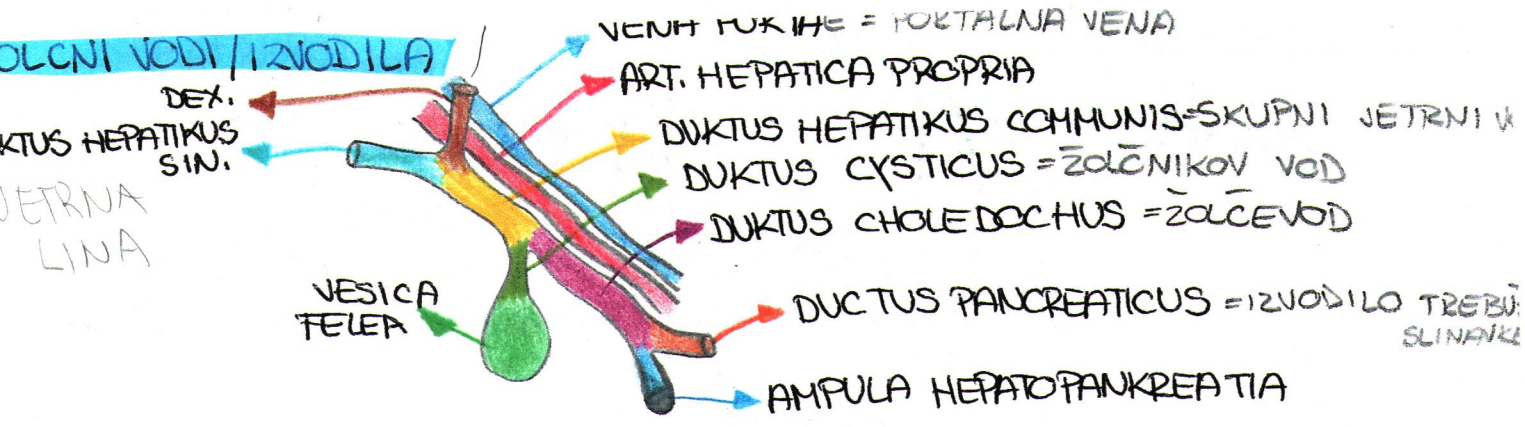


JETRA: VISCERALNA PLOŠKEV

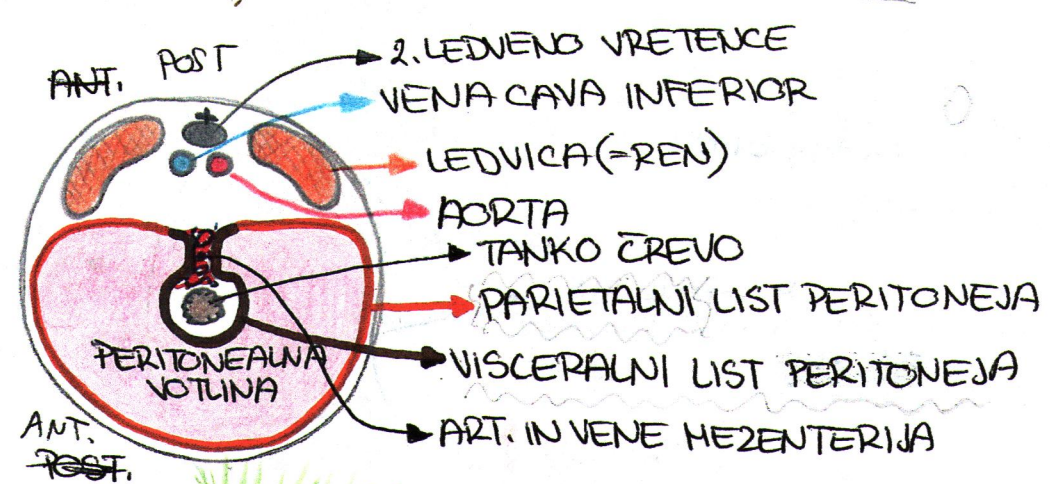


**KAJ VSTOPA IN IZSTOPA
SKORI VENO PORTAE**

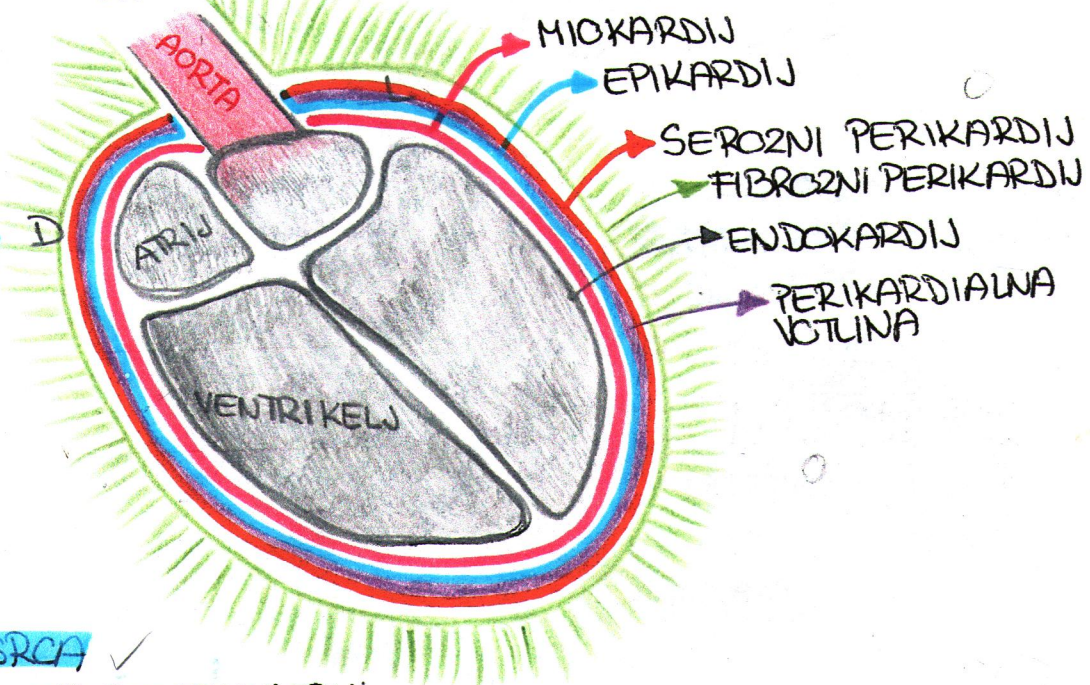




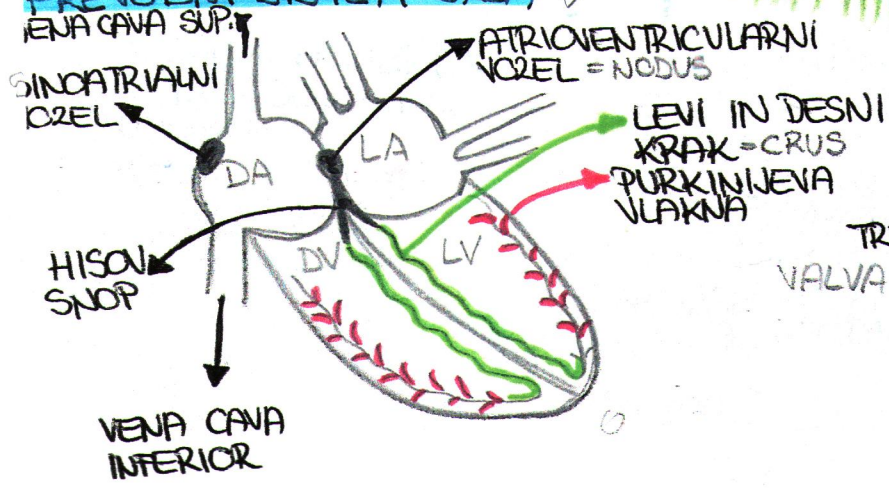
PREČNI / HORIZONTALNI PREREZ TREBUŠNE PLOTINE V VIŠINI L2: PERITONEJ - potek




OBTOKILA: FRONTALNI PREREZ SRCA / SRČNE STENE



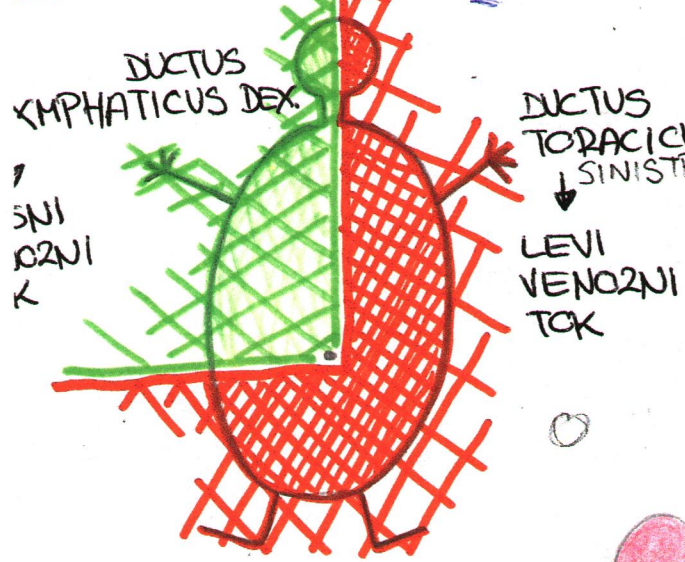
PREVODNI SISTEM SRCA



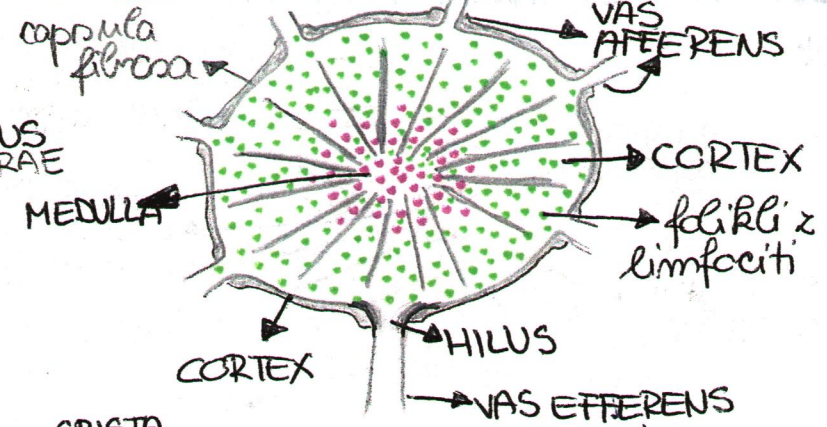
SRČNI SKELET OD ZGORE



TRNKOVNIK

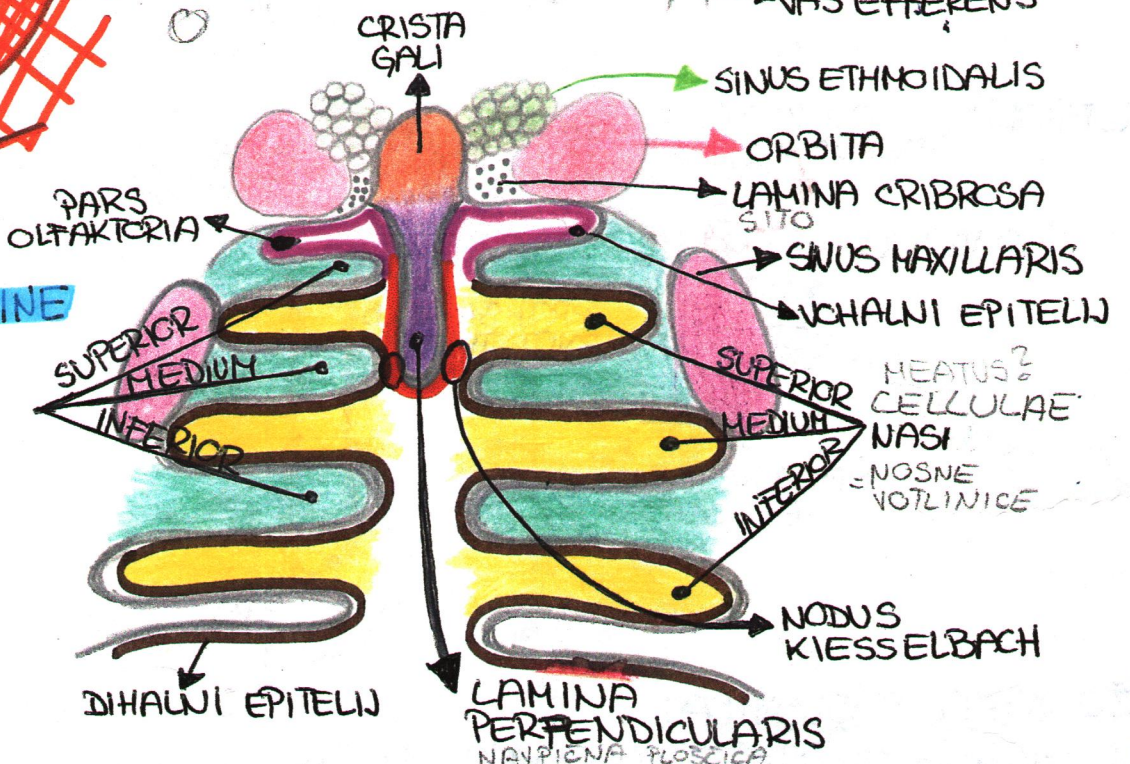


PREREZ BEZBENKE

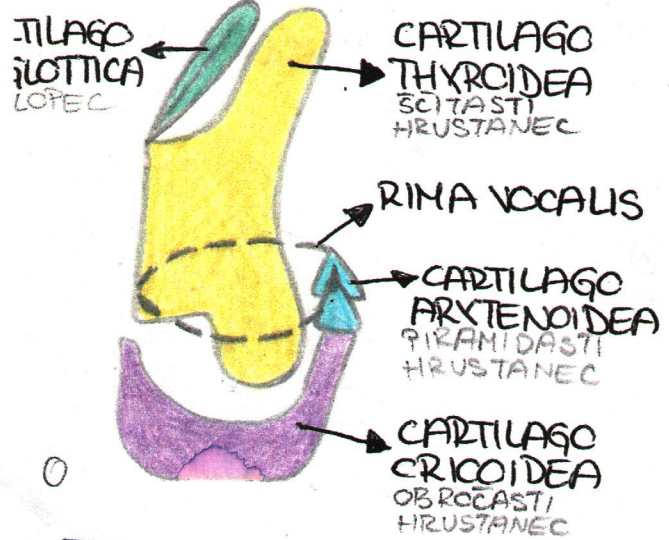


HALA: FRONTALNI PREREZ NOSNE VOTLINE

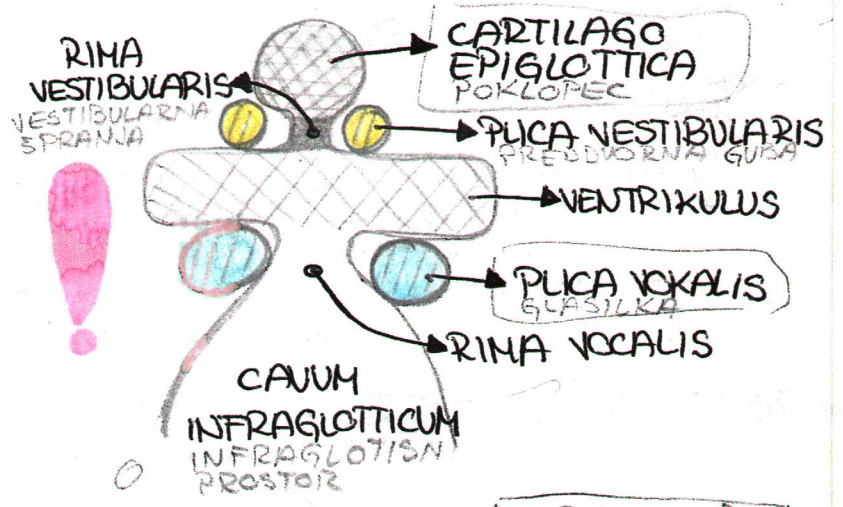
CONCHA NASALIS NOSNE SKOLJKE



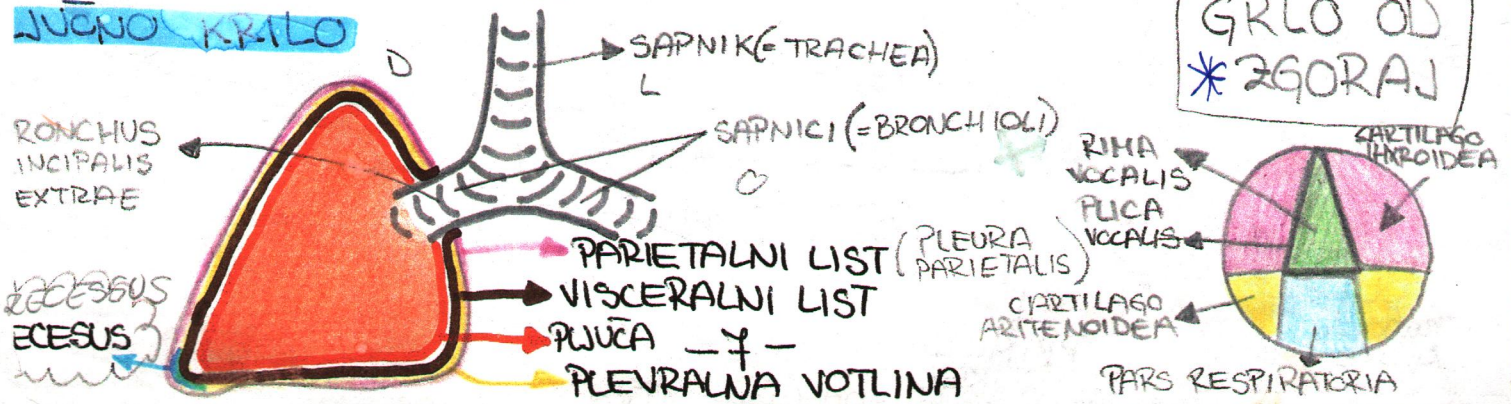
OSTANCI GRLA: LARINX



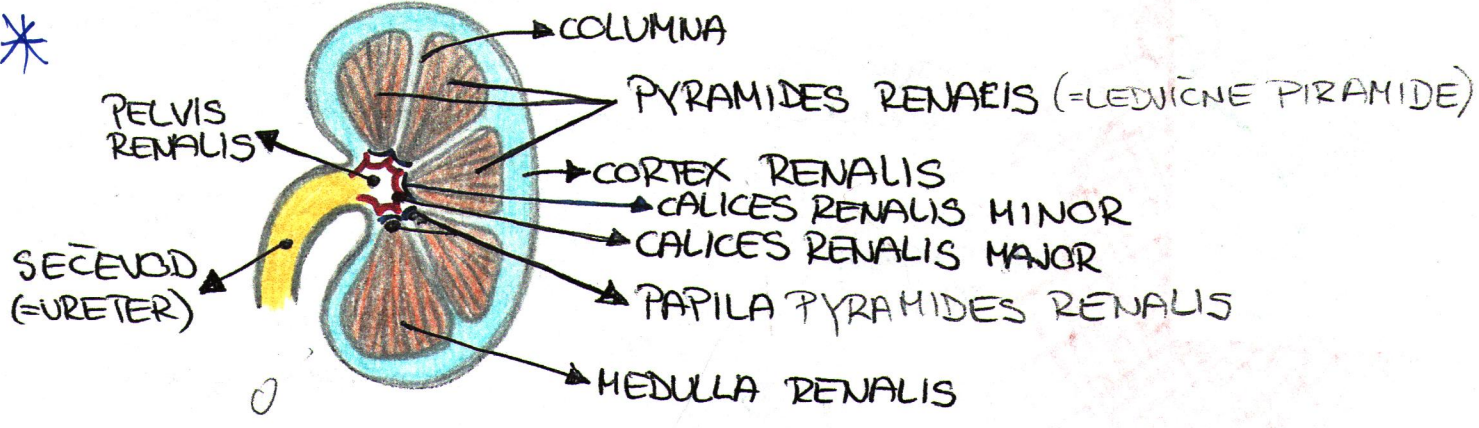
FRONTALNI PREREZ GRLA



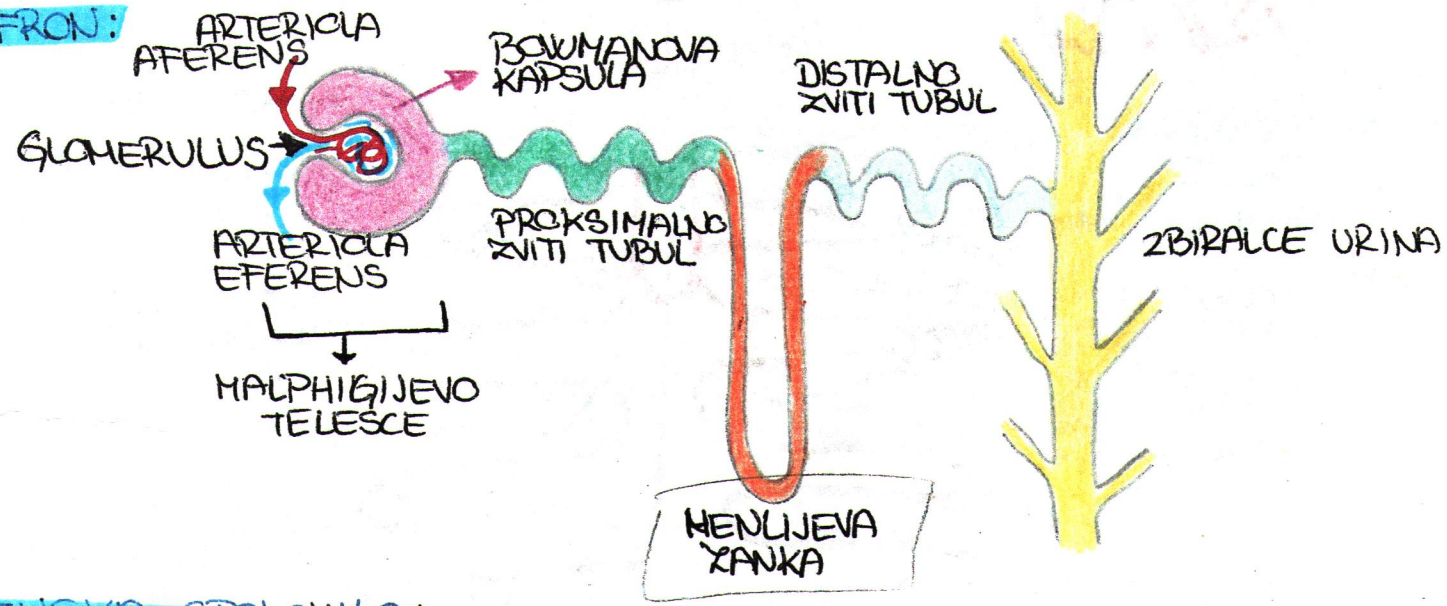
LUČNO KRILU



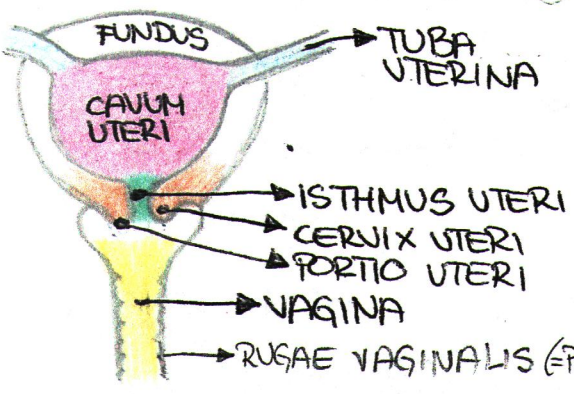
SEČILNA: FRONTALNI PREREZ LEDVICE - CELNI PREREZ



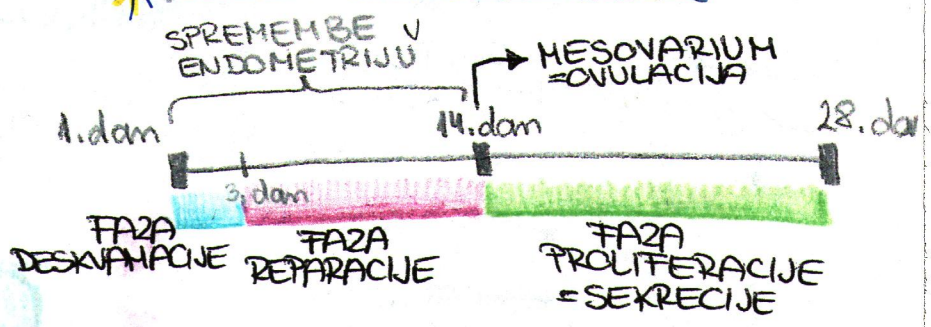
NEFRON:



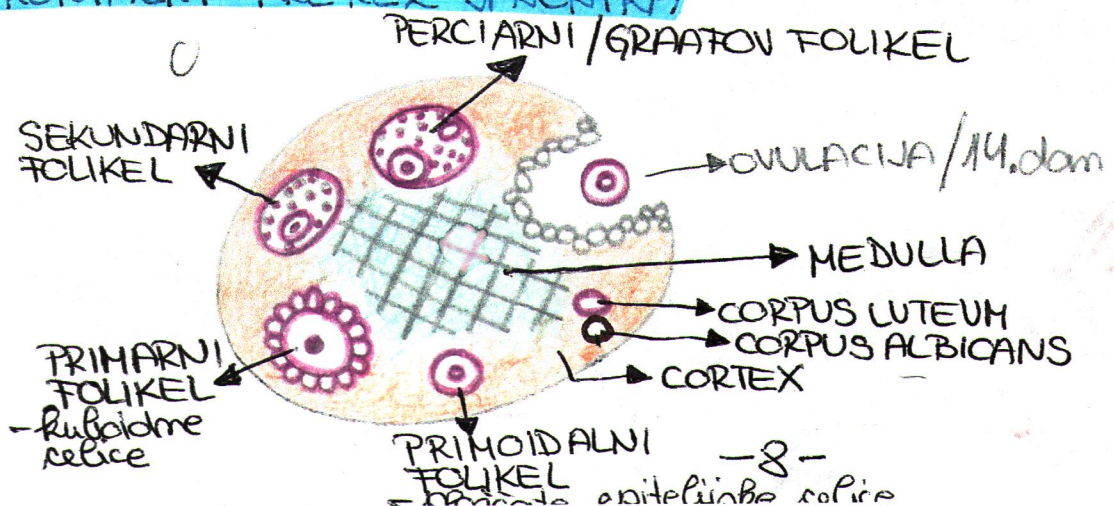
ŽENSKA SPOLOVILA: MATERNICA, NOŽNICA FRONTALNO



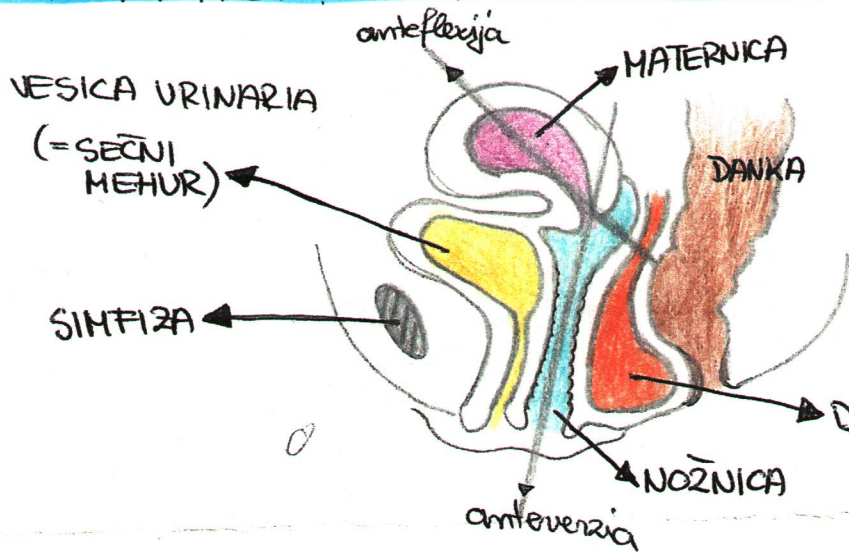
*** MENSTRUALNI CIKLUS**



FRONTALNI PREREZ JAJČNIKA



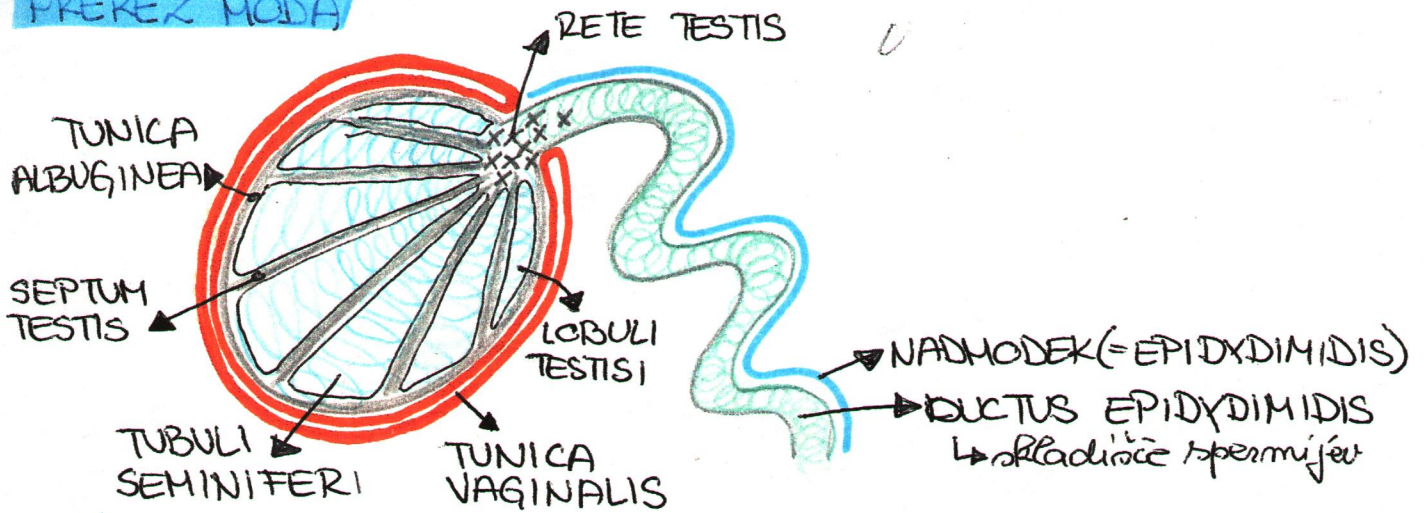
MEDIALNI PREKEZ ŽENSKE MEDENICE



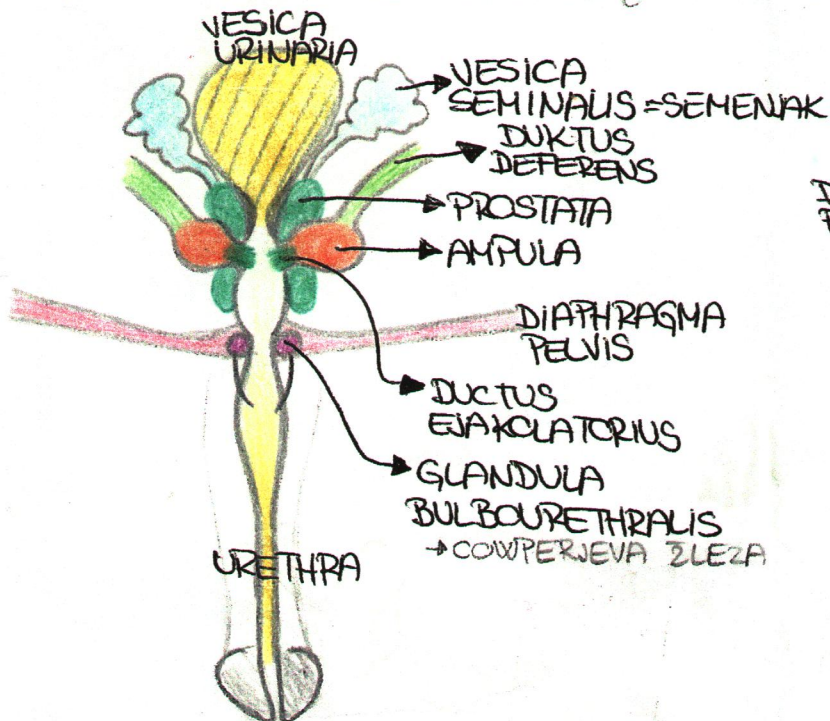
MATERNICA JE NAGNENA NAPREJ NA SEČNI MEHUR...

DOUGLASOV = najnižja točka peritonealnega prostora

MOŠKA SPOLONILA: FRONTALNI PREKEZ MODA



MOŠKO SPOLONILO: POGLED OD ZADAJ



TRANSVERZALNI PREKEZ PENISA

